Squamous cell carcinoma – 22 MHz

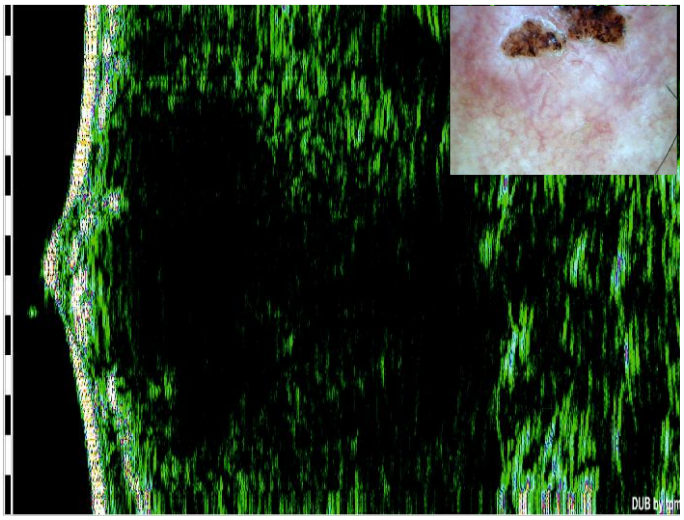

Non uniform epidermis thickness, hypo echogenic focus in dermis. By the reason of crust formation significantly broadened return echo, including total acoustic shadowing. After careful crust removal intermittent hypoechoic return echo, including blurred to the side-circumscribed, hypoechoic structure in the dermis, obscure circumscribed subcutaneous tissue.