Basal Cell Carcinoma / Basalioma – 22 & 75 MHz
Part 1

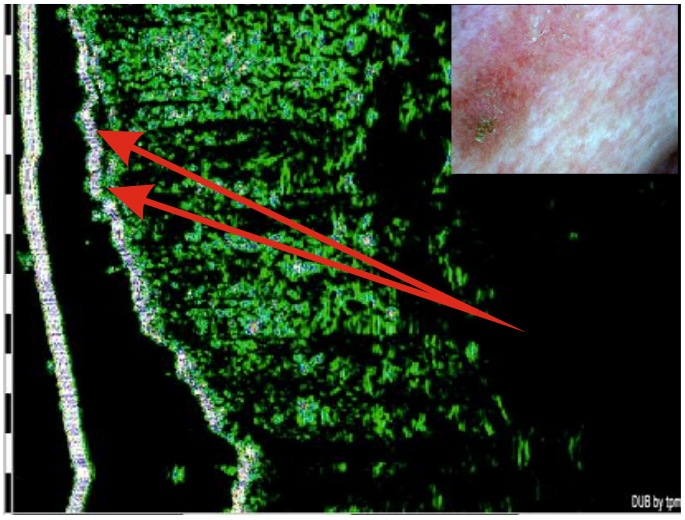

Superficial Basal Cell Carcinoma (BCC or Basalioma) with 75 MHz

Increased epidermis thickness up to 234 µm (normal epidermis 100 – 110 µm), intra epidermal or subdermal hypoechoic band, which can be explained by lymphocyte infiltration in subepidermal papillary area.

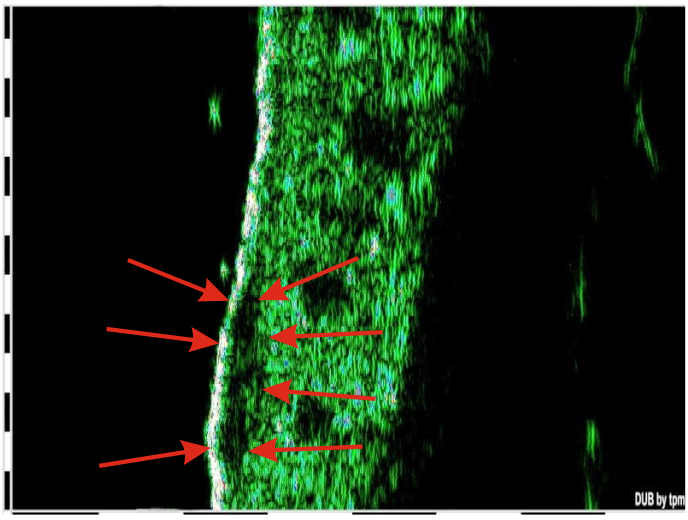

Superficial basal cell carcinoma, intraepidermal or subdermal hypoechogenic band of 0.6 mm depth with 22 MHz

Solid: The return echo is mostly hyperechoic and partially intermittent. A hypoechoic, mostly to the side and to the depth sharply defined structure with individual internal echoes is recognized in the dermis, there is often a subtumoural sound amplification.