Acne conglobata – 22 and 75 MHz

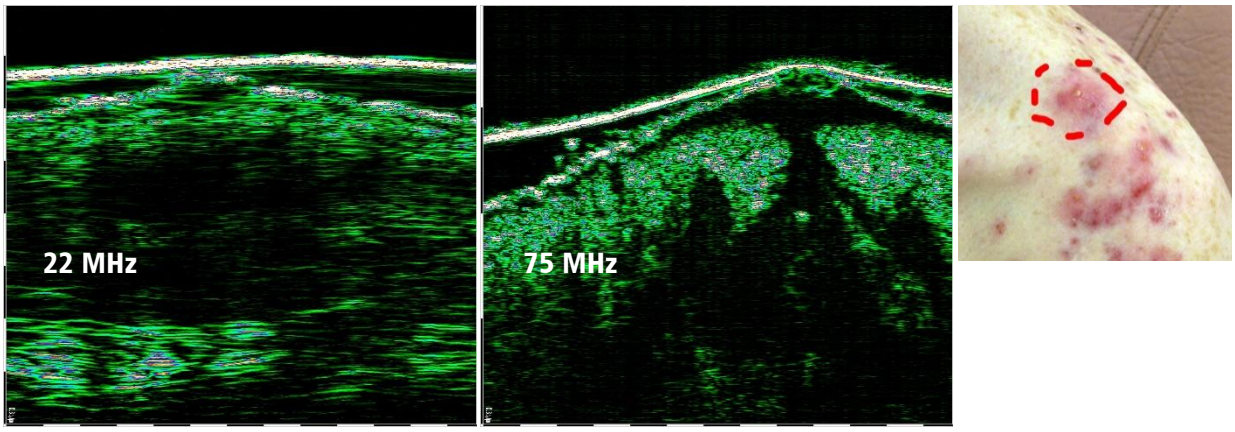

Diagnosis of the type and severity of acne to determine the depth, location and the volume of inflammatory infiltrates. The images of a 15 year old patient show several large infiltrates which are resistant to treatment on the shoulders.

On both scans (22 and 75 MHz) we see two hypoechoic areas, corresponding to inflammatory infiltrates – sub epidermal and intradermal-subdermal, occupying the middle and lower layers of the dermis and upper subcutaneous fat. Both infiltrates are connected to a hypoechoic area with 539x933 µm which is a transdermal fistula.