

**WHY YOU SHOULD USE HIGH-FREQUENCY  
ULTRASOUND DIAGNOSTICS  
IN ONCOLOGY**

# Content:

## **- Introduction**

- Frequencies and methods synergy
- HFUS and Histology

## **- Dermatology applications**

- Main applications
- Main pathological processes

## **- Aesthetic medicine applications**

- Fillers
- Thread-lifting
- High energy based treatment methods (lasers, RF, HIFU, etc.)
- Hypertrophic and Keloid scars differentiation
- Acne form diagnosis

## **- Oncology applications**

- General oncology application fields
- Simple malignancy criteria for skin tumor
- Melanoma – Breslow and Klark levels IN VIVO measurement
- Basal cell carcinoma types differentiation

## INTRODUCTION

Modern dermatology and aesthetic medicine require objective, reliable and safe diagnostic methods. Considering the difficulties of differential diagnosis in dermatology, high risk of side effects after aesthetic procedures, there is a strict demand for objective diagnostics of skin condition.

Today's diagnostic trends are focused on imaging methods that provide the most understandable and reliable visual information about the pathological object. It is always better to "see" the changed structure and location of the pathological site in order to choose the correct patient management.

Nowadays, the most common non-invasive skin diagnostic methods are video dermoscopy and high-frequency ultrasound (HFUS) skin imaging.

High-frequency ultrasound skin examination is a basic diagnostic method specially designed for the daily practice of dermatologists, derma-oncologists, aesthetic physicians and plastic surgeons. It makes possible any pathological changes detection in the skin and soft tissues.

It is well known that the higher the ultrasound frequency, the higher the resolution. Frequencies of 22 MHz and higher are used to diagnose surface structures such as the dermis, epidermis and subcutaneous tissue.

High-frequency ultrasound has a significant difference from traditional ultrasound with a probe frequency of 14-16 MHz, which is designed to examine deeper structures like liver, kidneys, muscles, etc.

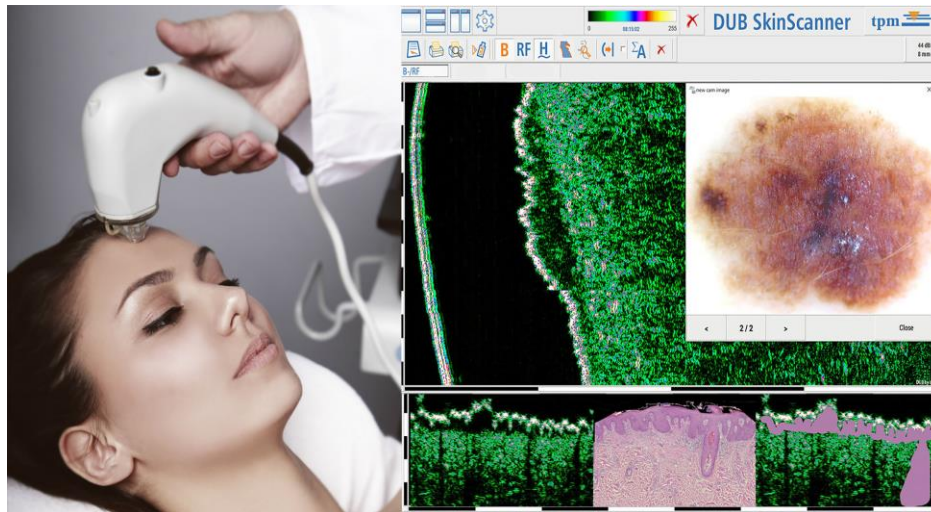
For the skin structure changes visualization probes from 22 to 100 MHz are required. These probes let doctors see the entire skin tissue and precisely examine the epidermis and dermis.

High scanning frequencies show the processes occurring directly in the vertical "skin slice cut" (from the epidermis to the subcutaneous fat). And resolution down to 21  $\mu\text{m}$  (75 MHz) helps to evaluate these lesions with maximum accuracy.

HFUS is the only way to see any changes in the skin's full thickness, giving a precise diagnosis for lesions. The combination of 22 MHz and 75 MHz HFUS with Doppler and cross-polarized video dermoscopy provides a complete tools set complex diagnosis of the required skin area. You can observe all pathological changes in different skin layers with a resolution of up to 21 microns, determine the characteristics of blood flow, and evaluate these changes on the skin surface using dermoscopy (50x magnification).

Ultrasound scans and dermoscopic changes can be displayed together on one screen, which is important for obtaining a complete picture of the skin lesion.

High-frequency ultrasound skin imaging has indisputable advantages: availability, reliability, high measurement accuracy, non-invasiveness, painlessness, safety and the ability to study the evolution of the same object in dynamics.



*HFU scan + videodermoscopic image*

High-frequency skin scans are similar in appearance to histologic images and are intuitively understood by dermatologists, aestheticians, oncologists, plastic surgeons, and other specialists involved in the diagnosis and treatment of skin lesions. These professionals have a good understanding of skin anatomy and histology, which simplifies the interpretation of HFUS scans.

The special software developed for HFUS skin images processing helps to study and accurately assess the morphofunctional skin parameters.

HFUS is widely used to examine the skin at various time intervals, documenting all features and changes. The data is digitized and stored in a database. It is easy to perform comparative analysis of images, see skin changes in dynamics and analyze the effectiveness of treatment. Today, HFUS could improve the service quality of any medical organization, especially those operating in the high-tech sector.

## ONCOLOGY

Dermatologists and aesthetic doctors are on the first line when treating patients with any skin neoplasms. They have to conduct primary diagnostics and define further tactics for patient management.

Derma-oncology is one of the most high-tech medical fields. There are many different modern treatment methods for skin tumors. However, first of all it is necessary to evaluate the size, border character, tumor depth and surrounding tissue condition, which is necessary for the correct clinical diagnosis. During this stage, the doctor determines if the lesion is malignant or benign. The final conclusion is usually made after histopathological tumor examination. But, before histology tumor must be removed with clear margins and minimal damage to surrounding healthy tissues.

**How to assess the neoplasm before histological examination, to avoid incomplete or unnecessarily excessive lesion removal? How to evaluate the dynamics of tumor treatment during long-term therapy?**

When working on the abdominal organs, there are many methods: MRI, computed tomography, X-ray, and ultrasound. For the skin, the only way to assess the depth of the pathological process, its boundaries and structure is to use high-frequency ultrasound.

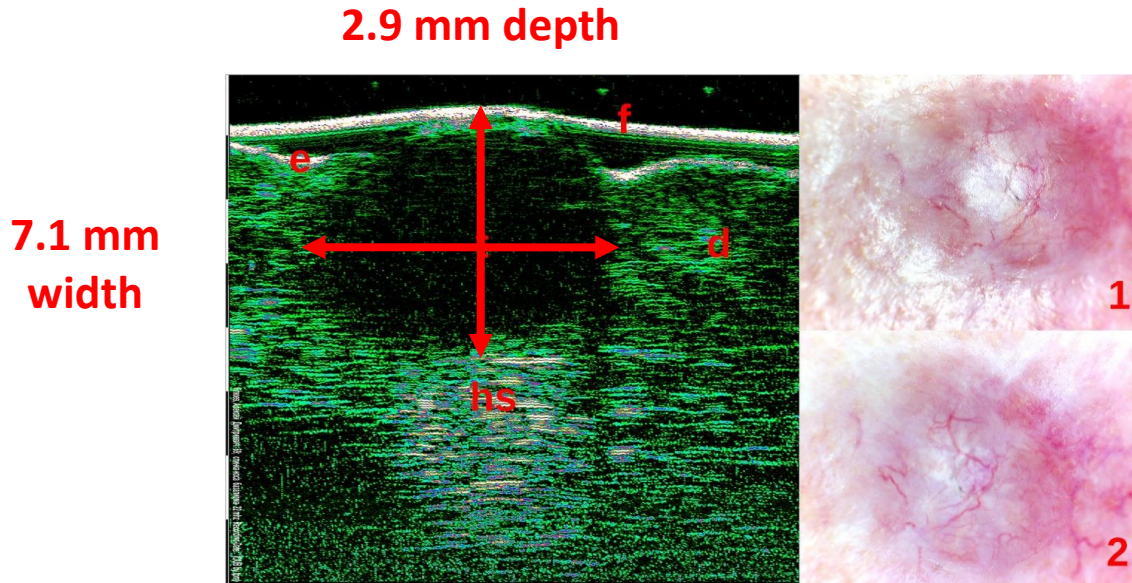
### **High-frequency ultrasound examination in oncology and dermasurgery applications:**

- Quick and accurate quantitative examination of the tumor structure, tumor invasion depth (epidermis, papillary dermis, reticular dermis, subcutaneous fat, etc.), tumor margins, and its characteristics.
- Determining the blood supply of tumors located in the skin.
- Choosing the optimal site for targeted biopsy.
- Measuring of the tumor size and surrounding tissue volume to be removed.
- Metastasis identification in the skin and subcutaneous tissue.
- For patients with suspected melanoma noninvasive defining of the BRESLOW index, CLARK stage, and TNM classification in vivo.
- Monitoring the completeness of skin tumor removal in order to prevent relapse.
- Evaluation of long-term results after neoplasm removal.

**The HFUS skin image on the scans is visually comparable with the histological picture. HFUS scans have a high resolution and are easily interpreted by specialists.** Many scientists refer to high-frequency ultrasound as in vivo biomicroscopy.

**Direct quantitative tumors HFUS measurement brings maximum reliability and objectivity. HFUS determination of tumor size, invasion depth, and margins and tissues in-**

involved in the neoplastic process is vital due to the lack of other available non-invasive methods for an objective assessment of structural changes inside the skin.



*Nodular BCC. High frequency ultrasound scan with tumor sizes, and videodermoscopy*

High-frequency scanning using probes 22 and 75 MHz, allows to use of simple **malignancy criteria** for skin tumor diagnosing by ultrasound signs. The most pronounced malignant features are: formation with a tendency of constant growth, uneven margins and vertical growth orientation of the tumor, which grows to the depth and has irregular blurred heterogeneity, vascularization and microcirculation are enhanced during Doppler imaging.

Benign signs: a long-term existing tumor without sufficient growth, with clear contours and margins with surrounding tissues, with superficial location in the epidermis and upper dermis, with a regular hypo- or hypo-heterogeneous pattern, and with undetectable blood flow during Doppler examination.

If one or more malignant signs are found, the tumor can be preliminary classified as malignant.

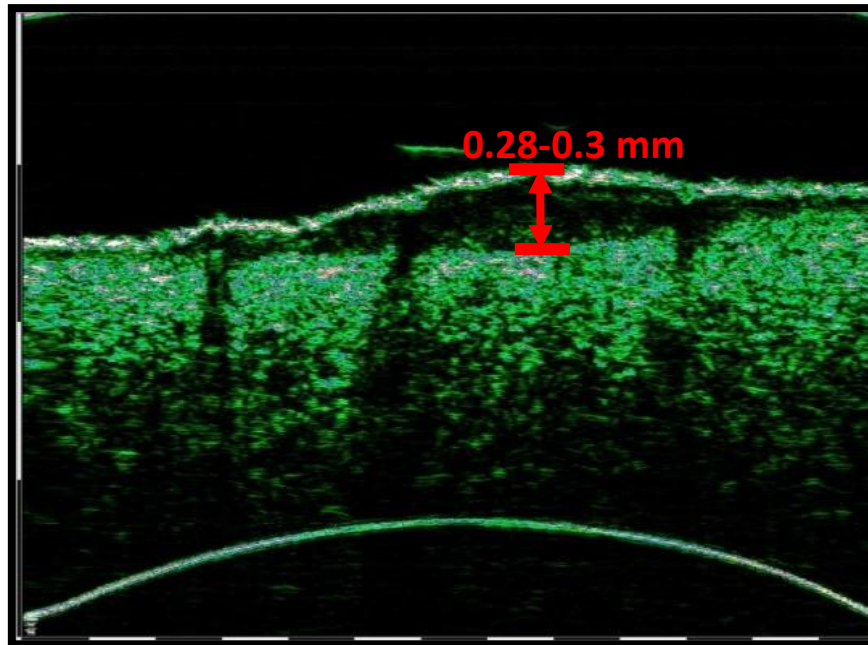
**MELANOMA.** Worldwide, there is a rapid increase in the incidence of skin malignant neoplasms, up to 3 million new cases of skin cancer per year. In the structure of skin malignant neoplasms, melanoma is 10% and there is a tendency to increase by 2.6-11.7% per year, mainly due to people of young working age.

The main prognostic melanoma factors are characteristics of the primary tumor such as Breslow index and Clark level of invasion, as well as sentinel lymph node status.

The surgical method is the main one in treatment of primary melanoma, and in order to reduce the metastasis probability, the volume of excision is determined by tumor thickness.

The thickness is determined after removal by histological examination. As a result, often there is a need for re-excision in accordance with the obtained Breslow index (according to the literature data up to 30%), thus in order to avoid a second operation, often much larger tissue volume is excised.

**Melanoma scan 75 MHz,**  
hypoanechoic tumor  
11 mm x 300  $\mu$ ,  
depth 140-190  $\mu$  from the  
skin surface  
**BRESLOW INDEX - 0**  
(melanoma thickness  
0.28-0.3 mm)  
**CLARK LEVEL - 2** (pene-  
tration into the papillary  
dermis layer)



Timely **NONINVASIVE** assessment of the tumor spread (thickness and level of invasion) before the treatment has fundamental importance, as it allows not only to make a diagnosis, but also to avoid hyperdiagnosis. HFUS tumor size and stage assessment allow to choose an adequate surgery volume, and plan the additional diagnostic procedures for the remote metastasis search, and plan the adjuvant chemotherapy and immunotherapy. It is important that in case of melanoma, high-frequency skin ultrasound allows the surgeon to plan the volume of excision exactly in accordance with the in vivo Breslow index before operation.

The high correlation between histomorphometric and high-frequency ultrasound measurements of tumor thickness determines the need to include ultrasound in the mandatory complex of preoperative skin tumors diagnostics.

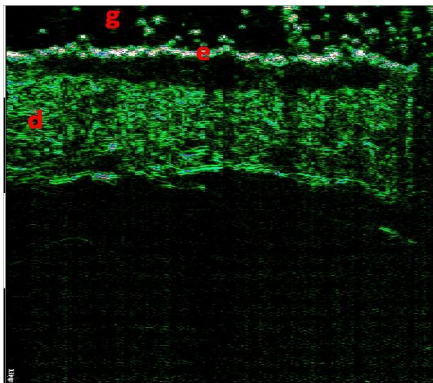
**BASAL CELL CARCINOMA.** The basis of the successfully chosen tactics for the BCC treatment is the correct assessment of the clinical-morphological form. High-frequency ultrasound makes it possible to differentiate BCCs types: superficial, nodular, scleroderma-like, and micronodular.

**Superficial** BCCs on ultrasound scans have horizontally elongated contours with a clear demarcation from the underlying dermis with a hypoechoic structure, while **nodular** BCCs are characterized by round or oval outlines with a diffuse hypo-heteroechoic structure and are also clearly demarcated from surrounding tissues. Often the dot-like inclusions visualized at tumor center and periphery. **Scleroderma-like** BCCs are visualized as hypoechoic formations with uneven outlines,

deeply penetrating into the dermis, with wavy fuzzy borders. **Micronodular BCCs** looks very similar with superficial, but the lower margin has uneven contours with pseudopodia-like outgrowths in the underlying dermis. Hyperechoic pinpoint inclusions were observed in superficial and nodular BCCs. In superficial BCCs pinpoint inclusions were mainly located along the periphery, and in nodular ones, inclusions were located in the tumor center and peripheral areas.

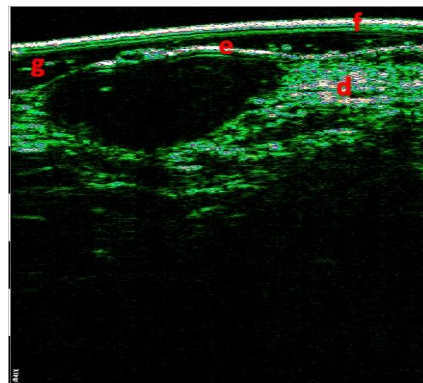
Patients often need for re-exicision, although all this can be avoided with a simple, painless, and visual method of ultrasound skin examination.

Differential diagnosis using high-frequency ultrasound imaging make possible early determination of the BCC clinical-morphological form, and choosing an adequate treatment method, control the treatment and reparation process and prevent relapse.



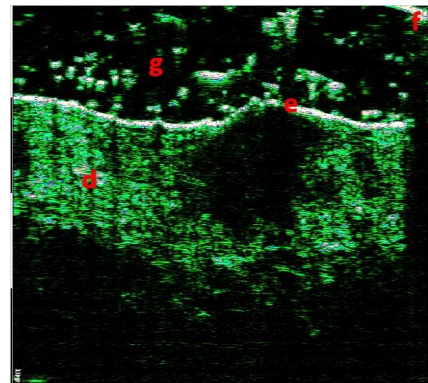
**SUPERFICIAL BCC**

- IMIQUIMODE
- PHOTODYNAMIC THERAPY
- CRYODESTRUCTION
- SURGICAL EXCISION



**NODULAR BCC**

- SURGICAL EXCISION
- RADIOTHERAPY
- BRACYTHERAPY



**SCLERODERMA-LIKE BCC**

- MOHS SURGERY
- SURGICAL EXCISION

**HFUS evaluates all morphological changes located in the skin at different levels: epidermis, dermis, and hypodermis.** That is why this method is indispensable and mandatory for medical institutions, it improves the quality of medical treatment, and the institution's status and expands the possibilities of providing high-tech medical care. HFUS is a useful tool for the right treatment method and the choice of its parameters, assess the lesion before treatment and monitor the treated area state after a certain time.

Thus, summarizing the information above, it should be noted that the purchase of a device for high-frequency ultrasound skin scanning is necessary for the daily practice of dermatologists and aesthetic doctors, and will provide high-quality and high technical medical services.