

**WHY YOU SHOULD USE HIGH-FREQUENCY  
ULTRASOUND DIAGNOSTICS IN  
DERMATOLOGY**

## Content:

### - **Introduction**

- Frequencies and methods synergy
- HFUS and Histology

### - **Dermatology applications**

- Main applications
- Main pathological processes
- Hypertrophic and Keloid scars differentiation
- Acne form diagnosis

## INTRODUCTION

Modern dermatology and aesthetic medicine require objective, reliable and safe diagnostic methods. Considering the difficulties of differential diagnosis in dermatology, high risk of side effects after aesthetic procedures, there is a strict demand for objective diagnostics of skin condition.

Today's diagnostic trends are focused on imaging methods that provide the most understandable and reliable visual information about the pathological object. It is always better to "see" the changed structure and location of the pathological site in order to choose the correct patient management.

Nowadays, the most common non-invasive skin diagnostic methods are video dermoscopy and high-frequency ultrasound (HFUS) skin imaging.

High-frequency ultrasound skin examination is a basic diagnostic method specially designed for the daily practice of dermatologists, derma-oncologists, aesthetic physicians and plastic surgeons. It makes possible any pathological changes detection in the skin and soft tissues.

It is well known that the higher the ultrasound frequency, the higher the resolution. Frequencies of 22 MHz and higher are used to diagnose surface structures such as the dermis, epidermis and subcutaneous tissue.

High-frequency ultrasound has a significant difference from traditional ultrasound with a probe frequency of 14-16 MHz, which is designed to examine deeper structures like liver, kidneys, muscles, etc.

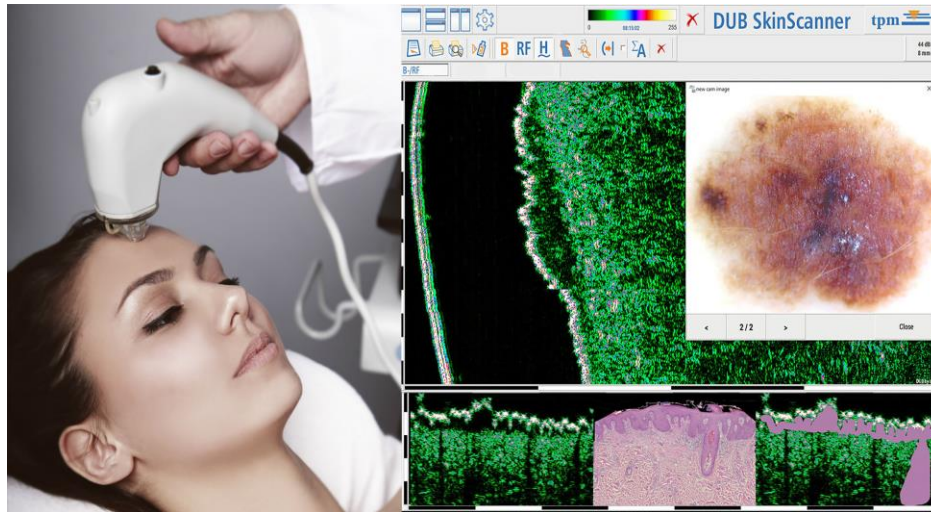
For the skin structure changes visualization probes from 22 to 100 MHz are required. These probes let doctors see the entire skin tissue and precisely examine the epidermis and dermis.

High scanning frequencies show the processes occurring directly in the vertical "skin slice cut" (from the epidermis to the subcutaneous fat). And resolution down to 21  $\mu\text{m}$  (75 MHz) helps to evaluate these lesions with maximum accuracy.

HFUS is the only way to see any changes in the skin's full thickness, giving a precise diagnosis for lesions. The combination of 22 MHz and 75 MHz HFUS with Doppler and cross-polarized video dermoscopy provides a complete tools set complex diagnosis of the required skin area. You can observe all pathological changes in different skin layers with a resolution of up to 21 microns, determine the characteristics of blood flow, and evaluate these changes on the skin surface using dermoscopy (50x magnification).

Ultrasound scans and dermoscopic changes can be displayed together on one screen, which is important for obtaining a complete picture of the skin lesion.

High-frequency ultrasound skin imaging has indisputable advantages: availability, reliability, high measurement accuracy, non-invasiveness, painlessness, safety and the ability to study the evolution of the same object in dynamics.



*HFU scan + videodermoscopic image*

High-frequency skin scans are similar in appearance to histologic images and are intuitively understood by dermatologists, aestheticians, oncologists, plastic surgeons, and other specialists involved in the diagnosis and treatment of skin lesions. These professionals have a good understanding of skin anatomy and histology, which simplifies the interpretation of HFUS scans.

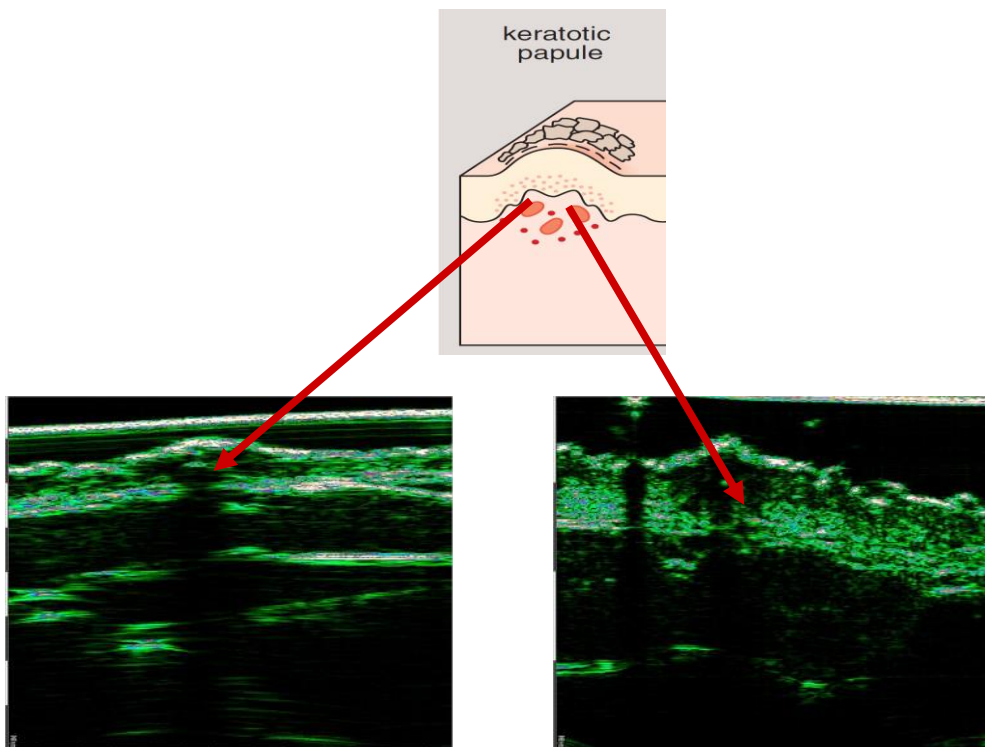
The special software developed for HFUS skin images processing helps to study and accurately assess the morphofunctional skin parameters.

HFUS is widely used to examine the skin at various time intervals, documenting all features and changes. The data is digitized and stored in a database. It is easy to perform comparative analysis of images, see skin changes in dynamics and analyze the effectiveness of treatment. Today, HFUS could improve the service quality of any medical organization, especially those operating in the high-tech sector.

## DERMATOLOGICAL APPLICATIONS:

- 1) Primary diagnosis in dermatology. HFUS visualization of skin lesions internal morphology helps to make a primary diagnosis.
- 2) Skin pathology differentiation (like infiltrative inflammation, exudative inflammation, purulent inflammation, necrosis, fibrosis, atrophy etc.)
- 3) Assessment of the disease stage, and severity, monitoring the dynamics.
- 4) Advanced diagnostics of morphological and functional changes in acute and chronic skin diseases, including cicatricial changes and lipodystrophy.
- 5) Differential diagnosis of dermatoses. Different pathology types have specific ultrasound features (patterns) that help to differentiate various skin diseases.

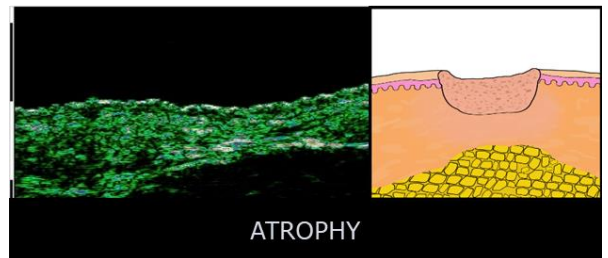
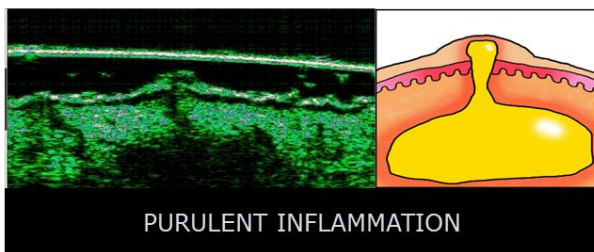
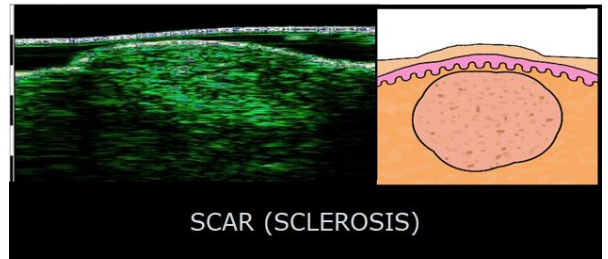
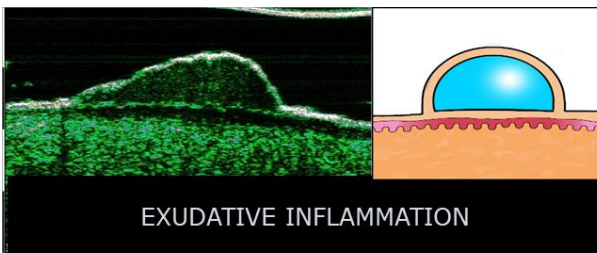
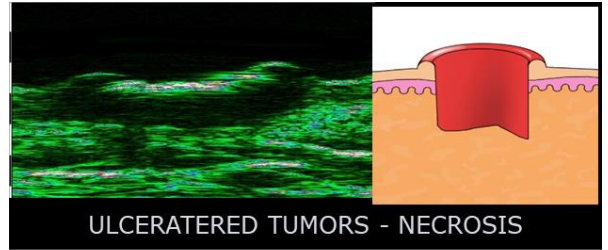
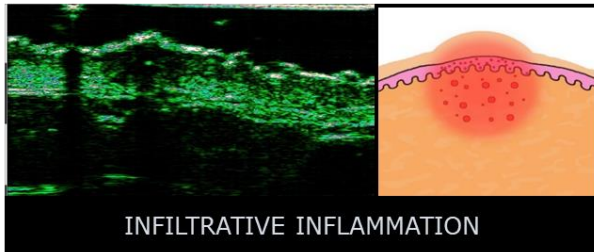
Ultrasound scanning is widely used by dermatologists worldwide to enhance diagnostic capabilities. This technique expands visualizations not only on the skin surface, like dermoscopy, but also throughout the depth.



*Psoriatic papules (22 and 75 MHz).*

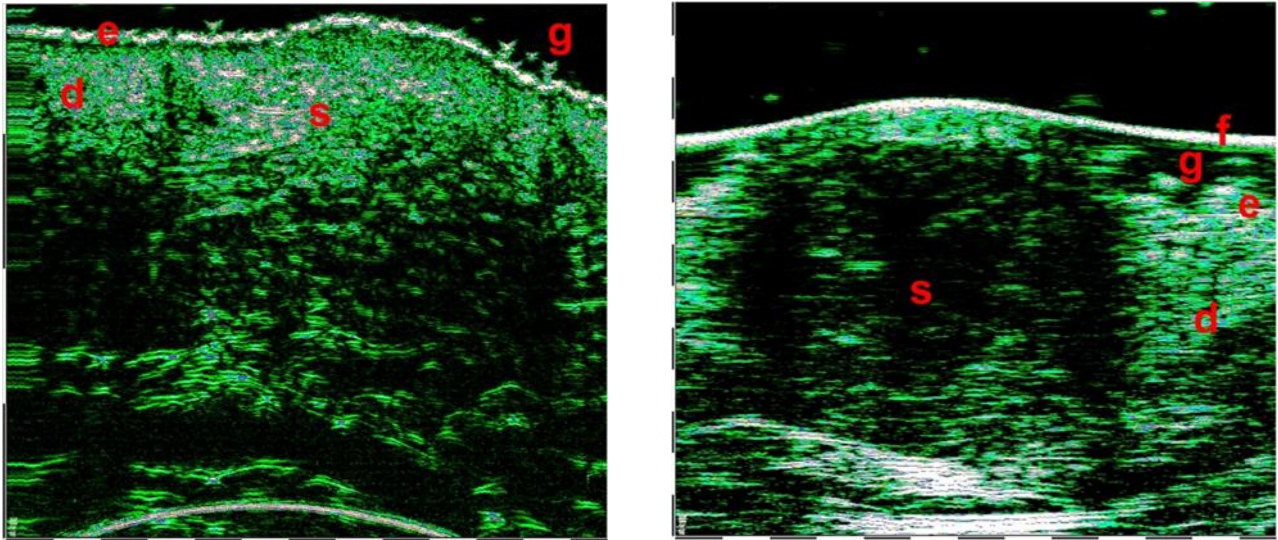
*Dyskeratoses and hyperkeratotic changes in the epidermis, inflammatory changes in the upper and middle dermis layers*

### Main pathological processes



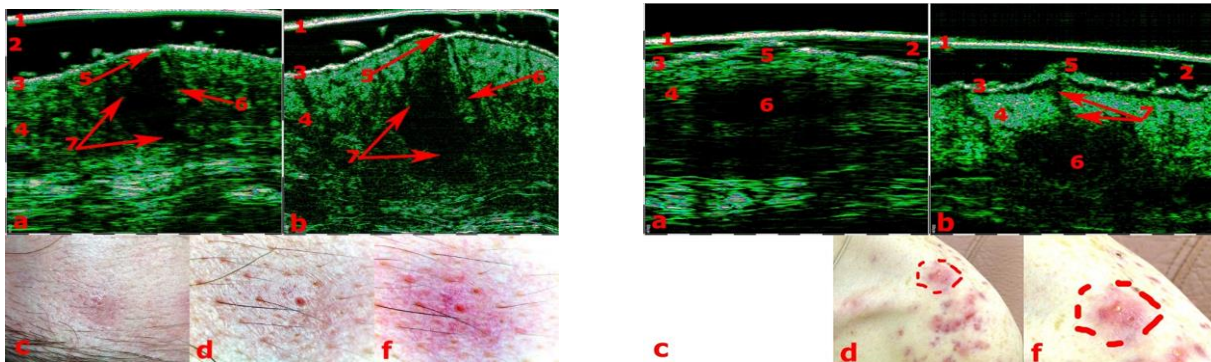
HFUS scans are convenient for dermatologists as they correspond to the histological description of any skin lesion, and allow clear visualization of morphological changes.

**Skin scarring is one of the valuable subjects in aesthetic medicine.** According to some recent studies, the HFUS data for the different scar types differentiation were obtained. **HFUS scars measurement and patterns analysis were successfully used for the normotrophic, hypertrophic, keloid, and atrophic scars differentiation.** This clinical information is vital for the scars proper treatment and rehabilitation.



**The HFUS hypertrophic(left) and keloid(right) scars differentiation.**

**HFUS acne examination is helpful for the precise acne form diagnosis (inflammatory/noninflammatory, pustules, conglobates, etc.).** For example, acne severity is very often underestimated, because internal changes in the dermis are invisible. HFUS examination allows to see the signs of infiltration, exudation, and fibrosis, which allows to diagnose acne type and follow proper treatment, with HFUS treatment efficacy control.



*Pustules' (left) and Conglobate(right) acne, the most pronounced changes are located in the dermis thickness. HFUS scans and videodermoscopic images*

**HFUS evaluates all morphological changes located in the skin at different levels: epidermis, dermis, and hypodermis.** That is why this method is indispensable and mandatory for medical institutions, it improves the quality of medical treatment, and the institution's status and expands the possibilities of providing high-tech medical care. HFUS is a useful tool for the right treatment method and the choice of its parameters, assess the lesion before treatment and monitor the treated area state after a certain time.

Thus, summarizing the information above, it should be noted that the purchase of a device for high-frequency ultrasound skin scanning is necessary for the daily practice of dermatologists, and will provide high-quality and high technical medical services.